ORIGINAL RESEARCH

PEER REVIEWED

An Open-Label, Proof-of-Concept Study Assessing the Effects of Bromelain-Based Enzymatic Debridement on Biofilm and Microbial Loads in Patients With Venous Leg Ulcers and Diabetic Foot Ulcers

Robert J. Snyder, Adam J. Singer, Cyaandi R. Dove, Stephen Heisler, Howard Petusevsky, Garth James, Elinor deLancey Pulcini, Aya Ben Yaakov, Lior Rosenberg, Edward Grant, Yaron Shoham

Keywords
Bacteria
Biofilm
Bromelain
Enzymatic Debridement
Diabetic Foot Ulcer
Venous Leg Ulcer

December 2023
ISSN 1943-2704

Index Wounds. 2023;35(12):E414-E419. doi:10.25270/wnds/23099

Abstract

Background. Most chronic wounds contain biofilm, and debridement remains the centerpiece of treatment. Enzymatic debridement is an effective tool in removing nonviable tissue, however, there is little evidence supporting its effect on planktonic and biofilm bacteria. **Objective.** This study evaluated the effects of a novel BBD agent on removal of nonviable tissue, biofilm, and microbial loads in patients with chronic ulcers. **Materials and Methods.** Twelve patients with DFU or VLU were treated with up to 8 once-daily applications of BBD and then followed for an additional 2 weeks. Punch biopsy specimens were collected and analyzed for biofilm, and fluorescence imaging was used to measure bacterial load. **Results.** Ten patients completed treatment, and 7 achieved complete debridement within a median of 2 applications (range, 2–8). By the end of the 2-week follow-up period, the mean ± SD reduction in wound area was 35% ± 38. In all 6 patients who were positive for biofilm at baseline, the biofilm was reduced to single individual or no detected microorganisms by the end of treatment. Red fluorescence for *Staphylococcus aureus* decreased from a mean of 1.09 cm^2 ± 0.58 before treatment to 0.39 cm^2 ± 0.25 after treatment. BBD was safe and well tolerated. **Conclusion.** Preliminary data suggest that BBD is safe and that it can be used to effectively debride DFU and VLU, reduce biofilm and planktonic bacterial load, and promote reduction in wound size.

Abbreviations

API, active pharmaceutical ingredient; BBD, bromelain-based debridement; DFU, diabetic foot ulcer; EPS, extracellular polymeric substance; GM-CSF, granulocyte-macrophage colony-stimulating factor; IL, interleukin; IQR, interquartile ratio; IRB, institutional review board; MMP, matrix metalloproteinase; PDGF, platelet-derived growth factor; SEM, standard error of the mean; SD, standard deviation; VLU, venous leg ulcer.

Introduction

Chronic wounds are estimated to affect over 6 million people in the United States alone.[1,2] The incidence is expected to increase as the population ages and as the number of individuals with obesity, systemic and peripheral vascular diseases, and diabetes increases.[1,2] Chronic wounds seriously affect the quality of life and productivity of the affected patient and result in substantial financial burden to the health care system. Lower extremity ulcers, especially those attributed to diabetes, venous disease, or arterial disease, comprise a substantial proportion of chronic wounds, with vascular and diabetic ulcers accounting for up to 98% of all lower extremity ulcers.[3]

A common feature of most chronic wounds is the presence of devitalized necrotic tissue. Devitalized tissue harbors bacteria and prevents or delays granulation and epithelialization, and removal (ie, debridement) of such tissue facilitates healing.[4] Moreover, the presence of a significant bacterial load in chronic wounds contributes to inflammation, wound infection, and further delays in wound healing.

Bacterial infection is the most important cause of chronic, nonhealing wounds. Chronic wound infections typically form biofilms, which are notoriously recalcitrant to antibiotics.[4] Bacterial biofilms are an ever-growing concern for public health, featuring both inherited genetic resistance and a conferred innate tolerance to traditional systemic and topical antibiotic therapies.[5]

Biofilm consists of a community of pathogens enveloped within a complex structure of entangled polymers that form a glycocalyx and are strengthened with metallic bonds and multiple species of bacteria and fungi. Within biofilm microbes secrete EPS, a protective matrix made from polymers, including proteins, glycolipids, polysaccharides, and DNA.[6] This glycocalyx protects the bacteria from antibiotics and accounts for the persistence of infection.[7] Additionally, these heterogenous bacterial colonies are resistant to systemic and local antibiotics, largely owing to their slow metabolic rates. Quorum sensing is another process that leads to antibiotic resistance.

Several methods are available for removing devitalized tissue and biofilm, including sharp surgical, mechanical, enzymatic, autolytic, and biosurgical (maggot) debridement. A few enzymatic debriding agents have been studied, including collagenase and bromelain.[8,9] Watters et al[10] developed a *Staphylococcus aureus* biofilm model that mimicked wound-like conditions and studied the antibiofilm activity of 4 enzymatic compounds. In that study, bromelain reduced biofilm biomass by 98%. Scanning electron microscopy confirmed detachment of the biofilm EPS and bacteria from the growth surfaces. The overall results of that study indicated that use of enzymes such as bromelain may be effective in eradicating biofilms and may be a promising strategy to improve the treatment of multidrug-resistant bacterial infections.[10]

Novel drug therapies (eg, BBD agent EscharEx [MediWound]) for debridement of hard-to-heal wounds are currently under development. The API is a concentrate of proteolytic enzymes enriched in bromelain extracted from pineapple plant stems for use in selective removal of nonviable tissue without damaging the underlying healthy tissue and while promoting granulation tissue formation. The intended use of BBD is based on several preclinical and clinical studies conducted on chronic wounds and burns in which fast, effective debridement was achieved compared with placebo and nonsurgical procedures.[2] This API formulation is the same active component contained in NexoBrid (MediWound), a product indicated for eschar removal (debridement) in adults with deep partial- and full-thickness burns that has been approved in 44 countries, including recently (December 28, 2022) in the United States by the Food and Drug Administration.[11-17]

BBD is intended to address the unmet need of debridement of VLUs, DFUs, and other chronic wounds by functioning as a fast and effective nonsurgical modality that promotes wound bed preparation. The resulting clean wound bed can then be treated with common wound management procedures aimed at promoting healing. Enzymatic debridement via this therapy may serve as a nonsurgical alternative that enables the removal of barriers that impair or delay wound healing, thus promoting healthy granulation tissue formation and facilitating healing and wound closure. Preliminary preclinical and clinical studies have shown that topical application of BBD results in rapid and effective wound debridement.[2,8,18] However, prior studies did not focus on the effects of this substrate on biofilm.

The main objectives of the current pilot study were to explore enzymatic debridement by means of BBD and to evaluate the safety of BBD and its effects on biofilm, bacterial burden, and wound size in patients with VLU and DFU.

Materials and Methods

Study population

The researchers recruited 12 adult patients (age range, 18–90 years) with a VLU or a DFU that had been present for at least 4 weeks but no longer than 2 years. The surface area of the target wound was between 2 cm^2 and 80 cm^2, with greater than 50% of the wound surface area covered by necrotic nonviable tissue or slough. Patients with more than 1 leg ulcer or with clinical evidence of infection (fever, purulent discharge, surrounding cellulitis, osteomyelitis) were excluded from the study. Patients with chronic skin disorders, suspected skin cancer, arterial insufficiency of the involved leg (ankle-brachial index <0.5), uncontrolled diabetes (HbA_{1C} level >12%), significant comorbidity (eg, chronic kidney, liver, lung, or cardiac disease), or use of systemic corticosteroids were also excluded. The study was conducted in 3 clinical sites in the United States and was approved by the central IRB. All study subjects signed informed consent forms.

Study interventions

Prior to application of the debriding agent, patients were administered an oral analgesic (eg, acetaminophen, ibuprofen) and all wounds were washed with soap and water. If necessary, topical anesthetic (eg, lidocaine, or a combination of lidocaine 4%, epinephrine 0.05%, tetracaine 0.5%) was applied 5 to 30 minutes prior to application of the debriding agent. As mentioned previously, BBD is extracted from the stems of pineapples; it consists of a mixture of proteolytic enzymes enriched in bromelain and comes as a lyophilized powder. The powder is mixed with a hydrating gel immediately prior to application.

The intact skin immediately surrounding the wound was protected using a topical barrier (eg, zinc oxide paste) that was carefully applied in a thin layer to avoid introducing it into the wound itself. Sterile isotonic (0.9%) sodium chloride solution was sprinkled on the wound to keep the wound moist during the application procedure. The BBD was applied at a dose of 28.1 g per 80 cm^2 wound area. After application, the wound was covered with an occlusive film, an absorptive covering, and a compression dressing for a mean of 24 hours ± 3. The wounds were assessed daily to determine if complete debridement had been achieved. If debridement was not complete, the therapy was reapplied up to 8 times daily (daily on weekdays only) or until complete wound debridement, whichever occurred first.

Prior to removal of the dressing, data regarding administration of any medications, adverse events, and assessment of pain and vital signs were recorded. After removal of the dressings, any dissolved nonviable tissue was removed by wiping it away with dry gauze or a tongue depressor and the wound was cleaned with either sterile saline solution or water and mild soap. Any loose tissue that could be easily lifted or separated from the wound bed was cut away. No other debridement technique was permitted.

At each daily assessment the wounds were photographed and assessed for wound size, amount of nonviable tissue, and presence of granulation tissue and safety parameters, such as surrounding erythema or edema. Following completion of the daily visits, patients were treated according to standard procedures and evaluated once weekly for an additional 2 weeks.

Before the initiation of treatment with BBD, full-thickness 3-mm punch biopsy specimens were collected from all wounds to assess for the presence of biofilm. Biopsy site selection was determined using a noninvasive device that detects elevated bacterial burden in and around wounds with high sensitivity based on bacterial autofluorescence (MolecuLight i:X; MolecuLight).[19,20] The fluorescence imager uses red and cyan fluorescence to detect elevated bacterial loads (>10^4 CFU/g). The area of pixels was converted to square centimeters by finding the pixel to area ratio from the fluorescent image via the corresponding detected area in the wound measurement image. Most bacteria fluoresce red; however, *Pseudomonas* uniquely fluoresces cyan.[20]

The wound biopsy samples were frozen at –70°C and cut into 5-mm–thick sections using a cryostat. The sections were then placed on glass slides and stained using Sytox green nucleic acid stain (Thermo Fisher Scientific, Inc) and Texas Red wheat germ agglutinin (carbohydrate) (Thermo Fisher Scientific, Inc) and examined using a Leica TCS SP5 confocal scanning laser microscope (Leica Microsystems GmbH). Wound fluid samples were collected from all wounds before initiating treatment and at the end of the study period for analysis of wound biomarkers, including MMP-2 (QuickZyme BioSciences [catalog No. QZBMMP2H]), MMP-9 (QuickZyme BioSciences [catalog No. QZBMMP9H]), human neutrophil elastase (Sigma-Aldrich Neutrophil Elastase Activity kit; MilliporeSigma [catalog No. MAK246-1KT]), IL-8, PDGF-BB, tumor necrosis factor receptor-1 (p55) (Ella Multiplex [3-plex]; ProteinSimple [Bio-Techne] [catalog No. SPCKC-PS-004433]), IL-1B, IL-1 receptor agonist, IL-4, GM-CSF, interferon-gamma (3rd Gen), tumor necrosis factor-alpha (2nd Gen), and IL-6 (2nd Gen) (Ella Multiplex [7-plex]; ProteinSimple [Bio-Techne] [catalog No. SPCKE-PS-005802]). Total protein was analyzed using the Pierce BCA Protein Assay Kit (Thermo Fisher Scientific; catalog No. 23225). Wound fluid was collected by absorption onto a piece of nonadherent gauze dressing, which was placed directly on the target wound. Biomarker analyses were done in accordance with manufacturer instructions.

Table. Quantification of Biofilm

BIOFILM	SCORE
No microorganisms	0
Single individual microorganism	1
Small micro-colonies (10-100 cells) of microorganisms	2
Large micro-colonies (>100 cells) of microorganisms	3
Continuous film of microorganisms	4
Thick (>10μm) continuous film of microorganisms	5

Study outcomes

The clinical performance outcomes included time to the first declaration of complete debridement as assessed clinically from the initiation of study treatment throughout the entire trial, incidence of complete debridement, and the number of treatment applications required to achieve complete debridement. Biochemical and microbiologic measures included levels of biomarkers in wound fluid, reduction in bacterial load, and reduction in biofilm after debridement. The biofilm was scored based on the number of bacterial colonies (**Table**). The researchers also assessed severity and incidence of systemic and local adverse events, vital signs, and laboratory parameters, as well as pain severity, on a verbal numeric scale of 0 to 10 (0, none; 10, worst).

Data analysis

Descriptive statistics were used to summarize the results. Categorical data were summarized as numbers and percentages. Continuous data were summarized as mean ± SD or median (IQR) based on their distribution. Owing to the exploratory nature of this pilot study, there was no sample size calculation.

Ethical considerations

This study was reviewed and approved by a central IRB and adhered to ethical guidelines and clinical research regulations, including patient consent forms.

Results

Twelve patients with VLU (n = 8) or DFU (n = 4) were recruited into the study. The mean age was 62 years ± 6; 7 patients (58%) were male and 5 were female (42%), 7 (58%) were White, and 4 (33%) were Hispanic. The median (IQR) wound duration was 23 weeks (6–34 weeks) and 16 weeks (14–22 weeks) for VLU and DFU, respectively. The median (IQR) wound surface area at treatment initiation was 3.5 cm^2 (2.7 cm^2–5.8 cm^2) and 3.4 cm^2 (2.7 cm^2–13.9 cm^2) for VLU and DFU, respectively. The median (IQR) percentages of nonviable tissue at baseline were 82% (72%–90%) and 65% (60%–75%) for VLU and DFU, respectively.

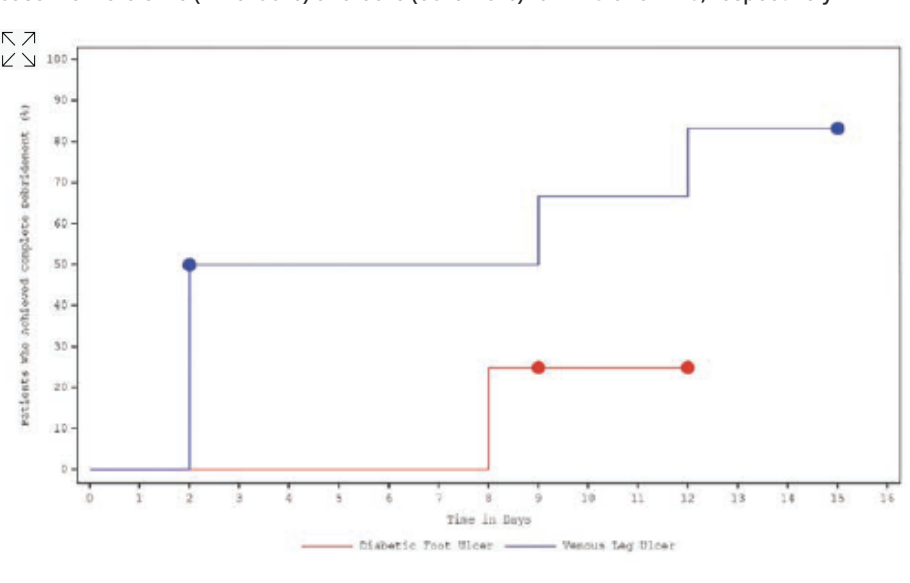

Figure 1. Kaplan-Meier plot of the time to complete debridement by cohort. Because the 50% threshold for complete debridement was not achieved in the diabetic foot ulcer cohort (red line), the median time to complete debridement was not calculated. Four of the 8 patients with venous leg ulcer (blue line) achieved complete debridement at day 2, and 1 of the 8 patients was censored. Day 2 was greater than the median. The median time to complete debridement of 5.5 days was based on the midway point between day 2 and the next observed complete debridement at day 9.

Complete debridement was achieved in 6 of 8 patients with VLU (75%) and 1 of 4 patients with DFU (25%). In patients with VLU who achieved complete debridement, the median time to complete debridement was 5.5 days, with a median of 6 applications of the debriding agent. A Kaplan-Meier survival analysis of the time course for debridement of VLUs and DFUs is presented in **Figure 1**. At the end of the treatment period, the median (IQR) wound area was 4.8 cm^2 (2.3 cm^2–7.9 cm^2) and 2.4 cm^2 (1.6 cm^2–8.8 cm^2) for VLU and DFU, respectively. At 2-week follow-up, the median (IQR) wound size was 4.4 cm^2 (2.2 cm^2–8.3 cm^2) and 0.9 cm^2 (0.6 cm^2–1.2 cm^2) for VLU and DFU, respectively.

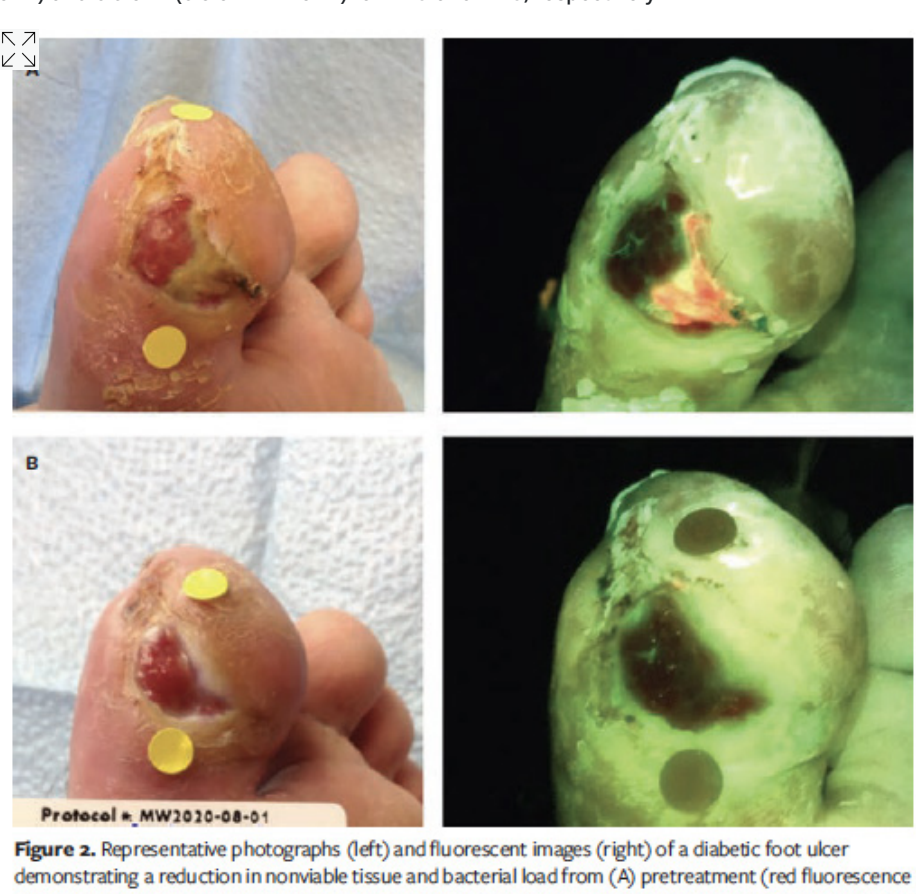

Figure 2. Representative photographs (left) and fluorescent images (right) of a diabetic foot ulcer demonstrating a reduction in nonviable tissue and bacterial load from (A) pretreatment (red fluorescence area, 0.84 cm^2) to (B) posttreatment with enzymatic debridement (red fluorescence area, 0.2 cm^2).

Autofluorescence

The mean (SEM) readings for red fluorescence for all patients decreased from 1.09 cm^2 (0.58 cm^2) prior to initiating enzymatic debridement to 0.39 cm^2 (0.25 cm^2) after the final treatment (**Figure 2**). However, according to the *t* test this difference was not significant ($P = .279$).

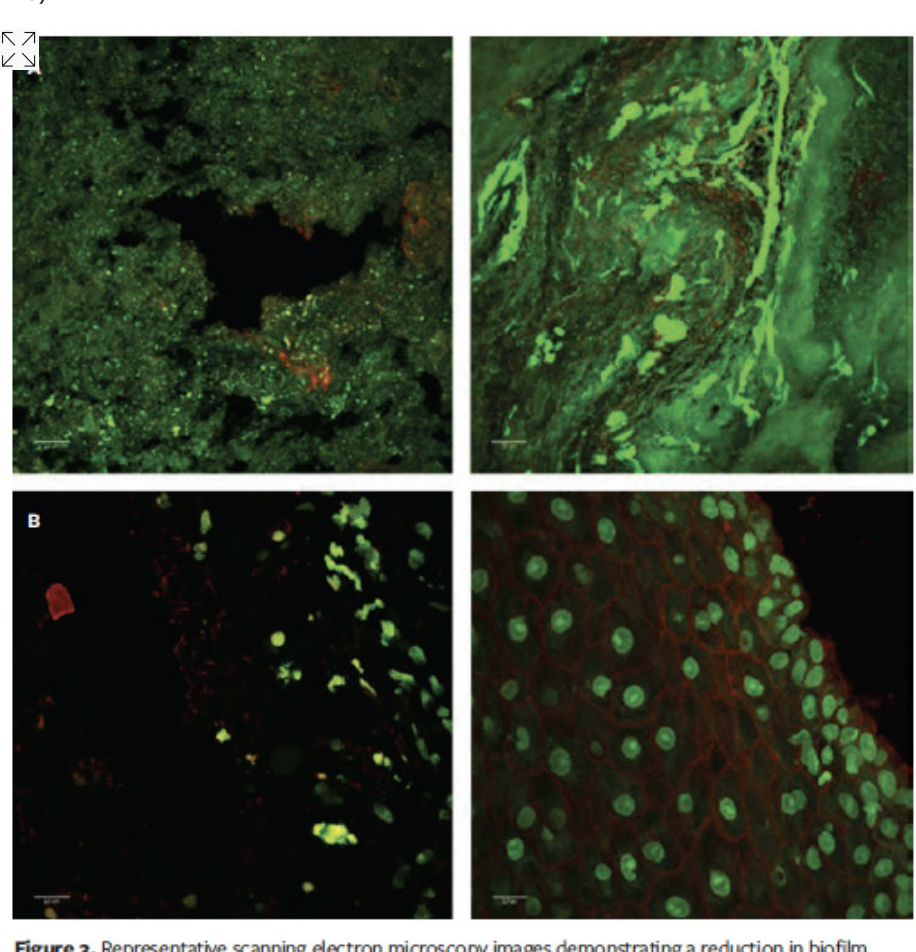

Figure 3. Representative scanning electron microscopy images demonstrating a reduction in biofilm from (A) pretreatment (biofilm score, 5 [thick continuous film of microorganisms]) to (B) posttreatment with enzymatic debridement (biofilm score, 1 [single individual microorganism]).

Wound biopsies

Wound biopsies for the presence of biofilm were evaluated for all but 1 patient, who did not undergo a second biopsy at the end of the study period. The mean biofilm score prior to treatment was 2.2 (range, 0–5). After treatment, the mean biofilm score was 1 (range, 0–3) (**Figure 3**). Only 1 patient had a higher biofilm score at the end of treatment than at the beginning of treatment.

Biomarker analyses

No significant changes were noted in the level of any biomarkers throughout the study in any study subject (data not shown).

Pain assessment and adverse events

Compared to baseline, there was a mean reduction in pain of –0.1 points ± 1.38 on a verbal numeric scale of 0 to 10 (0, none; 10, worst) at the last assessment and of –0.6 points ± 0.81 at the 2-week follow-up visit. In patients with DFU, the mean change in pain from baseline to the last assessment was 0.3 points ± 2.50 and from baseline to the 2-week follow-up visit was –1.3 points ± 0.58. In patients with VLU, the mean reduction in pain from baseline to the last assessment was –0.3 points ± 0.46 and from baseline to the 2-week follow-up visit was –0.4 points ± 0.74.

No adverse events or safety issues were reported.

Discussion

Chronic nonhealing wounds such as VLU and DFU represent a major health care burden.[21] While lower extremity ulcers have various etiologies, the presence of devitalized tissue and microbial contamination play a vital role in perpetuating nonhealing wounds. Wound bacteria can exist in 2 distinct, remarkably different states: planktonic and biofilm.[22]

Individual bacteria in the planktonic state, in which the germs are individual, have long been recognized and may be found in acute and chronic wounds. These bacteria are vulnerable to the innate and adaptive immune response as well as to various therapeutically administered antibacterial agents. In contrast, bacteria in chronic wounds exist mostly in the form of biofilm.

Biofilm is formed by multiple groups of bacteria that are held together by EPS matrix together with fungi filaments and spores. Polysaccharides within the biofilm facilitate adhesion to the wound and formation of a protective barrier, while proteins promote redox activities in the biofilm matrix. Possible explanations for the protective effect of biofilms on wound bacteria in addition to the insulation effect include paralysis and lysis of neutrophils and shifting of tissue macrophages to an alternatively activated state (M2 macrophages) with decreased microbicidal activity.[23] Biofilm may also attenuate the inflammatory response by reducing the expression of pro-inflammatory cytokines,[24] and it may form on any surface, including chronic wounds, foreign materials, and implants.[25] Biofilms may largely differ from each other by the nature and combination of the pathogen community bacterial species, various fungi, and the nature of EPS. The 3D structure of biofilm, heterogeneity of its constituents (some quite resistant to antimicrobial/antifungal medication), and its penetration into neighboring tissues contribute to the challenge of successfully eradicating it. Such eradication may necessitate wide and deep excision of the wound and its margin to remove the biofilm en bloc as a tumor.[26] Eradication of both the necrotic tissue and biofilm is critical for the effective management of chronic, nonhealing wounds such as VLU and DFU. Unfortunately, the results of biomarker analyses in the current study were inconclusive, possibly owing to the small sample size. Future, larger studies are necessary to further explore the temporal profile of wound biomarkers and their association with healing.

The main objectives of the current study were to explore the clinical performance, pharmacologic effect, and safety of a BBD agent in the debridement of VLU and DFU. Complete debridement was achieved in 7 of 8 patients with VLU but in only 1 of 4 patients with DFU.

The findings of this small pilot study suggest that enzymatic debridement with BBD may be a nonsurgical alternative in patients with VLU to allow the removal of physical and microbial barriers that impair or delay wound healing. Reductions in both biofilm and bacterial autofluorescence values were also noted. This further suggests that BBD may have a favorable effect on reduction of bioburden in both the DFU and VLU populations. Nonsurgical treatment of biofilm is extremely challenging, and the promise of a potentially effective topical medication is encouraging. Management of the ulcers with a BBD agent was also associated with a 35% reduction in wound area over the relatively short study period. Importantly, no significant safety concerns were observed with the use of this agent.

Limitations

This was a proof-of-concept pilot study and, as such, had a small sample size that was underpowered to detect small effects or adverse events. Furthermore, this was a single-arm, open-label study. Thus, there was no control group, and no comparative inferences could be gleaned from the data. The results may not be generalizable to other types of patients, ulcers, and settings. The primary focus of proof-of-concept studies typically is on demonstrating the feasibility or initial efficacy of a concept or intervention rather than conducting a thorough statistical analysis. Therefore, such studies represent preliminary investigations and often serve as the foundation for larger-scale initiatives.[27]

Conclusion

The preliminary data from the current study suggest that the BBD agent evaluated is safe and that it effectively debrides DFU and VLU, reduces biofilm and planktonic bacterial load, and promotes reduction in wound size.

Acknowledgments

Authors: Robert J. Snyder, DPM, MSc, MBA, CWSP[1]; Adam J. Singer, MD[2]; Cyaandi R. Dove, DPM[3]; Stephen Heisler, DPM, MHSA[4]; Howard Petusevsky, DPM[1]; Garth James, PhD[5]; Elinor deLancey Pulcini, PhD[5]; Aya Ben Yaakov, PhD[6]; Lior Rosenberg, MD[6]; Edward Grant, MPH[7]; and Yaron Shoham, MD[8]

Affiliations: [1]Barry University, Miami Shores, FL, USA; [2]Stony Brook University, Stony Brook, NY, USA; [3]University of Texas, San Antonio, TX, USA; [4]University of North Carolina at Chapel Hill, Chapel Hill, NC, USA; [5]Montana State University-Bozeman, Bozeman, MT, USA; [6]MediWound Ltd, Yavneh, Israel; [7]DP Clinical VP, Biostatistics and Clinical Data Management, Rockville, MD, USA; [8]Ben-Gurion University of the Negev, Beersheba, Israel

Disclosure: This study was funded by MediWound Ltd, Yavneh, Israel. Drs Snyder and Shoham serve as paid consultants for the sponsor of this study. Drs. Ben Yaakov and Rosenberg are employees for MediWound Ltd.

Correspondence: Robert J. Snyder, DPM, MSc, MBA, CWSP; 7301 N. University Drive, Tamarac, FL 33321; drwound@aol.com

Manuscript Accepted: October 24, 2023

How Do I Cite This?

Snyder RJ, Singer AJ, Dove CR, et al. An open-label, proof-of-concept study assessing the effects of bromelain-based enzymatic debridement on biofilm and microbial loads in patients with venous leg ulcers and diabetic foot ulcers. *Wounds*. 2023;35(12):E414-E419. doi:10.25270/wnds/23099